



# Italian Journal of Gynæcology & Obstetrics

June 2017 - Vol. 29 - N. 2 - Quarterly - ISSN 2385 - 0868

## Uterine artery embolization: An effective treatment option for uterine fibroids in Jehovah's Witnesses?

Sun-Yi Choe<sup>1</sup>, Seo-Hee Rha<sup>2</sup>, Jung-Woo Park<sup>1</sup>

<sup>1</sup>Department of Obstetrics and Gynecology, Dong-A University, College of Medicine, 26, Daesingongwon-ro, Seo-gu, Busan, 49201, Republic of Korea

<sup>2</sup>Department of Pathology, Dong-A University, College of Medicine, 26, Daesingongwon-ro, Seo-gu, Busan, 49201, Republic of Korea

### ABSTRACT

We introduce a case of vaginal expulsion of fibroids as a preoperative procedure. A 49-year-old woman (gravida 1, para 1) with vaginal bleeding and voiding difficulty visited the emergency room. She had a huge pedunculated submucosal fibroid, which prolapsed to the vagina. Uterine artery embolization (UAE) was performed as a preoperative procedure. She had experienced vaginal expulsion of fibroids, which made our surgical approach much easier. For patients who have symptomatic fibroids with difficulty in surgical approach, UAE can be suggested as a preoperative procedure because of the possibility of fibroid expulsion.

**Keywords:** uterine artery embolizations; uterine fibroid; expulsion

### SOMMARIO

Introduciamo un caso di espulsione vaginale dei fibromi come procedura preoperatoria. Una donna di 49 anni (gravida 1, para 1) con sanguinamento vaginale e difficoltà di svuotamento della vescica si è rivolta al pronto soccorso. Aveva un enorme fibroma sottomucoso con peduncoli prolapsato alla vagina. L'embolizzazione dell'arteria uterina (UAE) è stata eseguita come una procedura preoperatoria. Ha sperimentato un'espulsione vaginale dei fibromi, il che rendeva molto più facile il nostro approccio chirurgico. Per i pazienti con fibromi sintomatici con difficoltà di approccio chirurgico, l'UAE può essere suggerita come una procedura preoperatoria a causa della possibilità di espulsione dei fibromi.

### INTRODUCTION

Uterine fibroids, also known as uterine myomas, are the most common benign pelvic tumors, occurring in approximately 25% to 50% of women of reproductive age<sup>(1)</sup>. Some are asymptomatic, but others have symptoms, such as dysmenorrhea, menorrhagia, pelvic pain, infertility

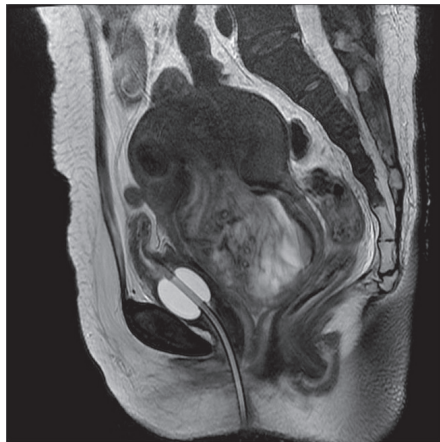and obstructive symptoms<sup>(1)</sup>. Treatment options for symptomatic patients vary, depending on their symptoms, age, desire of fertility preservation, and other clinical conditions<sup>(2)</sup>. Hormonal therapy such as Gonadotropin-releasing hormone (GnRH) agonist is sometimes used before hysteroscopic surgery for endometrium preparation<sup>(3)</sup>. However when hormonal therapy is contraindicated, uterine artery embolization (UAE) can be suggested as an alternative preoperative procedure. Also for

Corresponding Author: Jung-Woo Park: obgyppjw@dau.ac.kr  
Copyright 2017, Partner-Graf srl, Prato  
DOI: 10.14660/2385-0868-66

those who are contraindicated to surgery, UAE is an effective treatment for reducing vaginal bleeding and its size<sup>(4)</sup>. We present here a case of spontaneous vaginal expulsion of submucosal fibroid after performing UAE as preoperative procedure.

## CASE REPORT

A 49-year-old woman (gravida 1, para 1) visited the emergency department due to persistent vaginal bleeding for a month, with severe difficulty in voiding. She had a history of hysteroscopic myomectomy 4 years prior. She had no other obstetrical or past medical history. On pelvic examination, a fibroid mass, which was occupying the whole vagina, was found. Because of the mass transvaginal sonography (TVS) was impracticable. Magnetic resonance imaging (MRI) showed a  $7.5 \times 6.7 \times 9.5$  cm pedunculated submucosal fibroid with secondary degeneration, which prolapsed to the vagina (**Figure 1**).

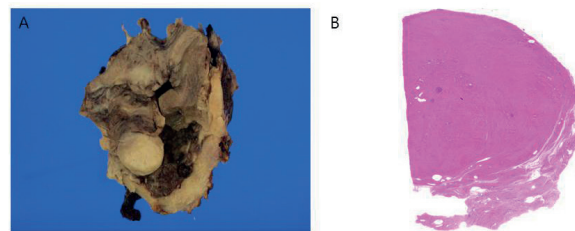


**Figure 1.** Sagittal magnetic resonance image demonstrates a  $7.5 \times 6.7 \times 9.5$  cm pedunculated mass at the upper vaginal cavity wherein the stalk is connected to the upper endometrium.

Her initial hemoglobin was 7.1 g/dL. Transfusion was needed, but the patient refused because she was a Jehovah's Witness, hence it was unacceptable. Our plan was to stop the vaginal bleeding first to increase the hemoglobin level and proceed with hysterectomy. GnRH agonist was initially administered, and intravenous iron was administered every other day. Despite these efforts, vaginal bleeding persisted, with a mean of 500 mL/day, and hemoglobin had decreased to 5.2 g/dL. Due to the risk of excessive bleeding, hysterectomy was unreasonable.

To stop the vaginal bleeding, UAE was performed on the bilateral uterine arteries. Contour particles (150–300  $\mu$ m) were used via coaxial micro-catheter system. The bleeding decreased dramatically. Although she was afebrile the day after the procedure, her white blood cell count was 18,150 / $\mu$ L, with 91.9% neutrophils, and 2.9 mg/dL C-reactive protein. A first-generation cephalosporin, cefazedone 1 g was injected intravenously, three times a day, and her white blood cell counts improved. She was discharged 2 days after the procedure.

One week after the procedure, she visited our gynecological clinic for outpatient follow-up and reported that the protruding uterine fibroid had spontaneously expelled through the vagina. She was asymptomatic. TVS revealed the uterus with a remnant fibroid in the endometrium. Although she complained of foul discharge, the vaginal bleeding was negligible, and her hemoglobin level increased to 11.0 g/dL, making it possible to perform the surgery. Because she had no intention for further pregnancy, total laparoscopic hysterectomy was done. The partial expulsion of the fibroid, which was located from the fundus to the vagina, made the procedure easier to perform. When the endometrium of the uterus was opened, a copious amount of foul-smelling brownish exudate was noted. Histopathologic finding showed necrosis of the fibroid, which was compatible with clinical findings (**Figure 2A & 2B**). She was discharged 4 days after the surgery, without any complication.



**Figure 2.** A. Gross finding of the uterine body cut section. The endometrium and myometrium are dark brown, edematous and ragged. B. The submucosal mass, which is suspected as leiomyoma, and adjacent myometrium show total necrosis. (H&E,  $\times 20$ )

## DISCUSSION

For patients with symptomatic uterine fibroids, such as menorrhagia, dysmenorrhea, pelvic pain and obstructive symptoms, such as urinary frequency, whom medical treatments have failed, hysterectomy could be another option. However,

the operative risk is high due to the bleeding during surgery, and performing hysterectomy on a patient who refuses blood transfusion, despite her hemoglobin level being low, is not reasonable.

UAE might be a treatment option to stop the vaginal bleeding and to reduce its size. UAE is frequently practiced as a nonsurgical treatment of symptomatic uterine fibroids since Ravina et al. first introduced this procedure for treatment of uterine fibroids in 1995<sup>(4)</sup>. This procedure has high treatment effectiveness with low complication rates. Fever, pelvic pain, and non-purulent vaginal discharge are common complications, which are mostly self-limiting<sup>(1)</sup>.

Another complication that mostly caught our attention was fibroid expulsion (FE) with an incidence of approximately 5%<sup>(5)</sup>. Marret et al. have reported that ischemic necrosis occurs after UAE, and this process may cause inflammatory reaction and prostaglandin secretion, leading to contractions<sup>(6)</sup>. Our patient's pathology result of total necrosis of the myometrium supports this process. Fibroids that are prone to expulsion are pedunculated submucosal fibroids and intramural fibroids that are involved with submucosal layers<sup>(5,7)</sup>. In addition, the use of GnRH agonist before the procedure was reported to increase the incidence rate of FE. This medication seems to shrink the myometrium greater than the myoma surface<sup>(8)</sup>.

When the fibroid is prolapsing, infection might occur through open cervix, which might accelerate FE by causing more inflammation. In a retrospective review conducted by Shlansky-Goldberg et al., 11% of patients with FE underwent emergency hysterectomy due to fever that was unresponsive to antibiotic treatment<sup>(7)</sup>. Mehta et al. reviewed 42 patients treated by

UAE, and 7 of these patients were readmitted because of infective complications. Three patients recovered by administering antibiotics, but antibiotic therapies failed in other 4 patients and they underwent total abdominal hysterectomy<sup>(9)</sup>. However, most cases of infection can usually be treated with antibiotics<sup>(10)</sup>, and we assumed that this complication can be prevented if used before the procedure.

In South Korea, UAE is not routinely recommended for patients with fibroids because the health care insurance service does not cover the cost of this procedure which makes myomectomy or hysterectomy more cost-effective. However, similar to our case, for patients who have symptomatic fibroids but cannot be treated with surgery because of the size and location of the fibroids and high operation risk, UAE can be suggested not only as treatment option but also as preoperative procedure because of the possibility of FE which will reduce the surgical risk. This procedure can also be recommended to patients who have not responded to hormonal therapy, as a less invasive treatment than surgery.

We recommend administering adequate antibiotics before the procedure to prevent infection. In addition, GnRH agonist can be administered before the procedure to promote expulsion. This suggestion can also lighten the burden of operative risks of patients who refuse blood transfusion, such as Jehovah's Witnesses.

#### CONFLICT OF INTEREST

No potential conflict of interest relevant to this article was reported.

## REFERENCE

- 1) Bradley LD. **Uterine fibroid embolization: a viable alternative to hysterectomy.** *Am J Obstet Gynecol.* 2009 Aug; 201(2):127-35.
- 2) Cheng MH, Chao HT, Wang PH. **Medical treatment for uterine myomas.** *Taiwan J Obstet Gynecol.* 2008 Mar; 47(1):18-23.
- 3) Laganà AS, Palmara V, Granese R, Ciancimino L, Chiofalo B, Triolo O. **Desogestrel versus danazol as preoperative treatment for hysteroscopic surgery: a prospective, randomized evaluation.** *Gynecol Endocrinol.* 2014 Nov; 30(11):794-7.
- 4) Ravina JH, Herbreteau D, Ciraru-Vigneron N, Bouret JM, Houdart E, Aymard A, et al. **Arterial embolisation to treat uterine myomata.** *Lancet* 1995 Sep 9; 346(8976):671-2.
- 5) Vural B, Ozkan S, Ciftçi E, Bodur H, Yücesoy I. **Spontaneous vaginal expulsion of an infected necrotic cervical fibroid through a cervical fistula after uterine artery embolization: a case report.** *J Reprod Med.* 2007 Jun; 52(6):563-6.
- 6) Marret H, Keris Yle B, Acker O, Cottier JP, Herbreteau D. **Late leiomyoma expulsion after uterine artery embolization.** *J Vasc Interv Radiol.* 2004 Dec; 15(12):1483-5.
- 7) Shlansky-Goldberg RD, Coryell L, Stavropoulos SW, Trerotola SO, Mondschein J, Beshara M, et al. **Outcomes following fibroid expulsion after uterine artery embolization.** *J Vasc Interv Radiol.* 2011 Nov; 22(11):1586-93.
- 8) Berkowitz RP, Hutchins FL Jr, Worthington-Kirsch RL. **Vaginal expulsion of submucosal fibroids after uterine artery embolization. A report of three cases.** *J Reprod Med.* 1999 Apr; 44(4):373-6.
- 9) Mehta H, Sandhu C, Matson M, Belli AM. **Review of readmissions due to complications from uterine fibroid embolization.** *Clin Radiol.* 2002 Dec; 57(12):1122-4.
- 10) Huang LY, Cheng YF, Huang CC, Chang SY, Kung FT. **Incomplete vaginal expulsion of pyoadenomyoma with sepsis and focal bladder necrosis after uterine artery embolization for symptomatic adenomyosis: case report.** *Hum Reprod.* 2003 Jan; 18(1):167-71.